

ETIOPATHOGENESIS OF KIENBOCK'S DISEASE

Still Indeterminate!!!

Dr. Monusha M, drapril88@gmail.com

Fellow Hand & Microsurgery; Ganga Hospital, Coimbatore

Dr. Neeraj Godara, neerajgodara@yahoo.com

Fellow Hand & Microsurgery; Ganga Hospital, Coimbatore

Dr. Praveen Bhardwaj, drpb23@gmail.com

Consultant- Hand Surgery; Ganga Hospital, Coimbatore.

Background:

Kienböck disease is a condition of uncertain etiology that results in osteonecrosis of the carpal lunate.^[1, 2] In 1843, Peste presented the initial description of lunate collapse in the French literature. Nearly 70 years later, the Viennese radiologist Robert Kienbock introduced the term '*lunatomalacia*' to describe the condition that now bears his name. It has been over 109 years since Kienbock published the article but the exact cause for this condition still remains an enigma. Kienböck believed that traumatic rupture of the ligaments and vessels around the lunate produced lunate fracture with subsequent collapse.

The true natural history of this condition is not well understood, and hence there are so many treatment options described.

There are numerous theories proposed as the cause or predisposing factors of Kienbock's disease which includes negative ulnar variance,

shape of the lunate, blood supply to the lunate, trabecular pattern and so on.

This article presents the science behind the proposal of these factors and corresponding research into the same.

Negative Ulnar Variance:

Hulten in 1928 first described the association of ulna negative variance with Kienbock's disease. An ulna negative variance was found in 74% of the patients with Kienbock's disease while only 23% of the 400 normal wrists had a short ulna. He suggested that the shorter ulna results in increase loading of the lunate over the ulnar edge of radius and advocated shortening of radius to offload the lunate. Shortly thereafter, Persson presented the option of lengthening the ulna to restore normal ulnar variance. Negative ulnar variance as a predisposition was further supported by Gelberman et al.³ However, this association between the ulnar negative variance and Kienbock's disease has been refuted by D'Hoore and few others⁴.

In spite of the controversy in the association between negative ulnar variance and the Kienbock's disease, radius shortening still remains one of the most commonly performed operations for the patients of Kienbock disease with negative variance.⁵

Blood Supply of the Lunate:

Arterial Supply:

The lunate is articular in its great proportion with four articular surfaces (proximal, distal, medial and lateral) all around through which blood

supply cannot enter. The blood vessels enter it through its non-articulating volar and dorsal surfaces.

There have been many conflicting studies on the vascularity of the lunate. Stahl and Lee studied cadaveric lunates and concluded that lunate has a sole volar blood supply. Based on this, Marek suggested that severe hyperextension of the wrist compromised this volar blood supply.

Grettv, Barber and Gelberman confirmed the presence of consistent dorsal and volar nutrient vessels with internal anastomosis and hence refuted the above theories based on the interruption of the volar blood supply. Gelberman demonstrated three patterns of intraosseous vascularity namely the Y, I and X out of which Y being the most common. The I pattern had a single volar and dorsal artery anastomosing in a single line. They proposed that if there are insufficient intra-osseous anastomoses (7%), this could be a predisposing factor for Kienbock's disease.⁶




Figure 1: Three Patterns of intraosseous vascularity of Lunate

Their study showed that flexion and extension strains and ligamentous injuries of the lunate are unlikely causes of avascular

necrosis of the lunate owing to its profuse external vascular supply. Also, lunate and perilunate dislocations were unlikely causes of necrosis.

A horizontal fracture of the lunate leading to avascular necrosis of the proximal pole as in the case of scaphoid has also been suggested, however a primary lunate fracture leading to necrosis has rarely been found.

The aseptic emboli theory by Axhausen also got disapproved by the improved knowledge of the vasculature.

Venous drainage of the Lunate:

Schiltenswolf et al suggested that venous congestion may play a role in necrosis of the lunate as in the case of femoral head necrosis.⁷ They recorded the intraosseous pressure in 12 normal and 12 necrotic lunate bones in neutral position and 60 degrees extension of the wrist under normal condition and venous stasis. The intraosseous pressure of capitate was taken as reference as it rarely gets necrotic. They observed that the increased pressure during extension matched the pressure found during venous stasis and assumed that it may be due to impaired venous drainage.

The venous outflow problem as the cause of Kienbock has been supported by the good results achieved by core decompression. However, a scientific proof of venous cause is still awaiting confirmation.

Compartment syndrome of the bone:

Combining both the arterial and venous aspects, the avascular necrosis has been suggested to be the result of compartment syndrome of the bone.

The factors that have an impact on the osseous compartment pressure are arterial supply, venous drainage, emboli and the marrow. Ischemia causes interstitial edema and the marrow fat cells become swollen which in turn leads to sinusoidal tamponade thus decreasing the venous outflow. This further increases the compartment pressure, reduces arterial inflow and finally necrosis ensues. Necrosis can occur due to localized venous hypertension from the stress fracture, which affects the sub articular venous plexus, or due to global hypertension from obstruction of the single volar vein. The venous obstruction causes fat cell edema, which in turn leads to hypertension.

Shape of the Lunate:

In 1966 Antuna Zapico evaluated the shape of the lunate and divided it into three types depending on the angle between the lateral scaphoid and proximal radial side of the lunate. The type 1 lunate is trapezoidal in shape with an angle greater than 130 degrees. This type is often seen in relation to negative ulna variance. Type 2 is of rectangular shape and has an angle of about 100 degrees. Type 3 has two distinct proximal facets, one articulates with radius and other with the TFCC, and lunate has the shape of a triangle. Zapico suggested that the type 1 lunate is a predisposition for Kienbock's disease because the trabecular pattern in type 1 is least able to tolerate the axial loading as the angulation is the largest.

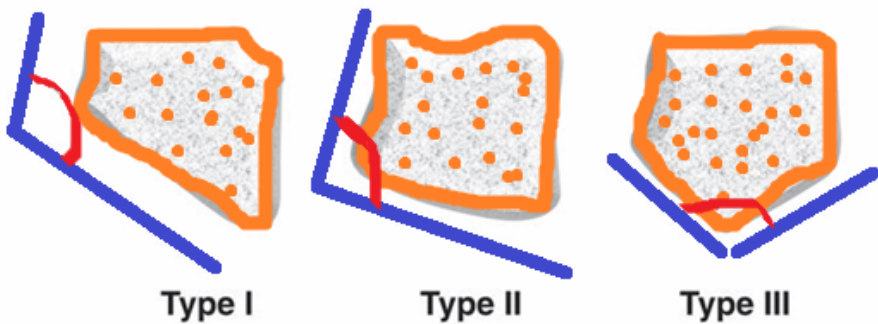


Figure 2: Shapes of lunate (Zapico Classification)

Viegas in 1990 classified lunate based on the presence of a medial facet. The lunate with a single facet positions the capitate in a more radial position and there is preferential loading through the midcarpal articulation and the radiolunate articulation tends to load in the same location. Type 1 lunate are more liable to collapse and progress to carpal instability. In type 2 lunate it has two articular facets distally for capitate and hamate and these are more prone for midcarpal arthritis.

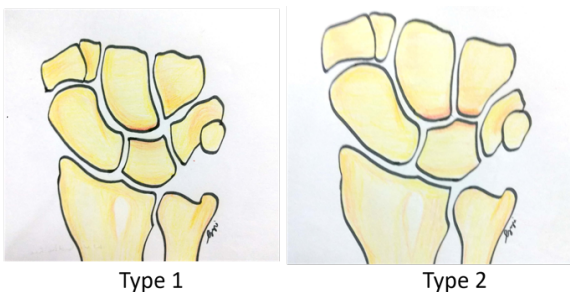


Figure 3: Shapes of lunate (Viegas Classification)⁸

It is also found that a smaller lunate which inclines more radially is prone for Kienbock's disease.

Microanatomy of the Lunate:

Trabecular architecture of the Lunate

In 1936 Frank established that the trabeculae are perpendicular to the articular surfaces and are related to mechanical loading. The bone trabeculae in bones are nearly perpendicular to the proximal and distal articular surfaces in the frontal plane, making a 72 to 108 degree angle with the subchondral bone, so as to resist the compressive load. In lunate bone, where the proximal and distal articulating surfaces are not parallel, these trabeculae are less able to resist to compression forces.

The studies on micro anatomy of the lunate by Bain showed that the common site of Kienbock's disease is the proximal articular "condyle". This proximal subchondral bone has a single trabecular plate which measured only 0.1 mm in thickness. So, when the repetitive loading causes stress fracture it commences in the single thin proximal subchondral bone plate. It acts as a cantilever and the stress fracture occurs at the point where the fulcrum loads the cantilever.

If the proximal and distal articular surfaces of the lunate are not perpendicular to each other, as in Zapico type 1 lunate, the trabeculae will not be in line to resist the compressive forces and the repetitive loading causes stress fracture that commences in the single thin proximal subchondral bone plate.

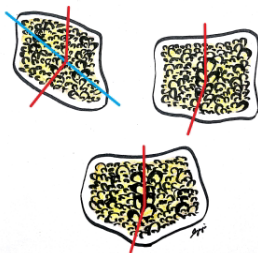


Figure 4: Trabeculae pattern in various shapes / types of lunate

Morphology of the Radius:

The morphology of the radius has also been found to have an association with the Kienbock's disease. A flat distal radial articular surface can predispose to Kienbock's disease by increasing the load on the radial aspect of the lunate.

The “Uncovered” Lunate:

The morphological factors like the negative ulnar variance, Viegas type I lunate and Zapico type I lunate ultimately increase the loading on the radial aspect of the lunate. The so-called “uncovered” lunate loads on the ulnar lip of the radius. The proximal subchondral bone is a cantilever and the stress fracture occurs at the point where the fulcrum loads the cantilever.

Personal factors:

Age and Gender

Kienbock disease is said to be slightly more common in men. Heavy manual work is not considered as a factor in causation. Among women patients, few are involved in manual labor, the dominant hand is not more likely to be involved and the disease is often discovered at a later age. Several cases have been reported in children, including ones as young as 6 years old.⁹ The course is more favorable than in adults, with or without treatment. Cases have been reported in the elderly patients as well.

Associated diseases:

Kienbock's disease can be found more commonly in people who have medical conditions that affect the blood supply, and it is also associated with diseases like lupus, prolonged intake of steroids, sickle cell anemia and cerebral palsy. Current research is focused on ant phospholipid antibodies, which are a fairly common finding in Kienbock's disease.

Relation with Trauma:

Trauma has been considered as a factor in the causation of the disease since its description by Kienbock. However, in various studies only about half of the patients report a history of significant traumatic event. Nevertheless, the microtrauma to the weakened bone could be present more often. The micro traumatic etiology was favored in the 1960s; it has been revisited for occupational disease.

Stahl observed that the condition was most frequently seen in the dominant hand of male labourers. Traditionally it is considered as an occupational disease caused by low frequency hand-arm vibration of 8-50 Hz or by work related trauma. It is listed under the number 505.01 in the European listing of occupational diseases in countries such as Germany and France. A minimum of 2 years of exposure to vibrating tools was introduced in Germany in 1965 on the basis of expert opinion. But limited evidence is present to establish hand arm vibration as a predisposing or causative factor for Kienbock's disease.

However, a recent systematic review has not found enough evidence to label the Kienbock's disease as occupation disease.¹⁰

Association with other types of Carpal Osteonecrosis:

Cases have been reported of associations with osteonecrosis in other carpal bones (scaphoid, capitate, entire proximal row), which suggests a regional disease.

To Sum up...

A systematic review of the aetiopathogenesis of Kienböck's disease was done by Stahl. They reviewed all the articles published since the first article by Kienbock in 1910 up to July 2012. A total of 220 references were found. The four most frequently discussed factors were negative ulnar variance (47%), primary arterial ischemia of the lunate (41%), trauma (41%) and hand-arm vibration (35%).¹⁰

Current Hypotheses

Probably, there are more than one factors involved in predisposition and causation of the Kienbock's disease, which when present in combination leads to the disease. Mechanical factors, acute trauma and repeated micro trauma no longer seem to be primary factors that cause the disease, but instead are factors that make symptoms of pre-existing Kienböck's disease worse. The disease seems to correspond more to a biological phenomenon, probably vascular and non-traumatic, with a proximal subchondral infarction, followed by attempted repair through creeping substitution, where there is more osteoclastic resorption activity than osteoblastic repair activity, for reasons that are still unknown. Genetic, viral and metabolic theories must still be developed,

as they could provide avenues for genetic or molecular treatment in the initial stages of the disease.

The enigma of Kienbock's disease is not yet solved and search for the true cause is still on...

References:

1. Lutsky K, Beredjiklian PK. Kienböck disease. *J Hand Surg Am*. 2012 Sep. 37(9):1942-52.
2. Bain GI, Yeo CJ, Morse LP. Kienböck Disease: Recent Advances in the Basic Science, Assessment and Treatment. *Hand Surg*. 2015 Oct. 20 (3):352-65.
3. Gelberman RH, Salamon PB, Jurist JM, Posch JL. Ulnar variance in Kienböck's disease. *J Bone Joint Surg Am*. 1975;57(5):674-6.
4. D'Hoore K, De Smet L, Verellen K, Vral J, Fabry G. Negative ulnar variance is not a risk factor for Kienböck's disease. *J Hand Surg Am*. 1994;19(2):229-31.
5. Shin YH, Kim JK, Han M, Lee TK, Yoon JO. Comparison of Long-Term Outcomes of Radial Osteotomy and Nonoperative Treatment for Kienböck Disease: A Systematic Review. *J Bone Joint Surg Am*. 2018;100(14):1231-1240.
6. Gelberman RH, Bauman TD, Menon J, Akeson WH. The vascularity of the lunate bone and Kienböck's disease. *J Hand Surg Am* 1980;5:272-8.
7. Schiltenswolf M, Martini AK, Eversheim S, Mau H. [Significance of intraosseous pressure for pathogenesis of Kienböck disease]. [Article in German] *Handchir Mikrochir Plast Chir*. 1996;28(4):215-9.

8. Viegas SF, Wagner K, Patterson R, Peterson P. Medial (hamate) facet of the lunate. *J Hand Surg Am* 1990;15:564–71.
9. Irisarri C, Kalb K, Ribak S. Infantile and juvenile lunatomalacia. *J Hand Surg Eur Vol.* 2010;35(7):544-8.
10. Stahl S, Stahl AS, Meisner C, et al. A systematic review of the etiopathogenesis of Kienböck's disease and a critical appraisal of its recognition as an occupational disease related to hand-arm vibration. *BMC Musculoskeletal Disorders.* 2012;13:225.